

ARCH CITY FOOT & ANKLE

DERMAGRAFT CASE STUDY PRESENTED BY:

DR. DENNIS TIMKO DPM

Patient's history

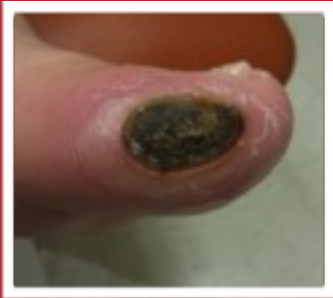Patient is a 67 year old male with Type II Diabetes, neuropathy in the lower extremities, and digital deformity of the great toe.

Diagnosis

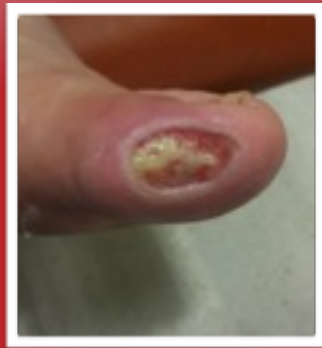6 month year old diabetic toe ulcer that has been treated with H₂O₂ by PCP without resolution.

Wound treatment & outcome

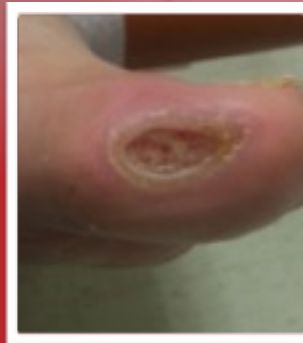The patient's ulcer healed completely after 3 weekly applications of Dermagraft over a 3 month period.



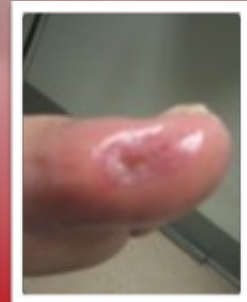
Date: 08/25/2010
Pre-Debridement
Wound Size: 1.2cm x
1.9cm x 0.4cm



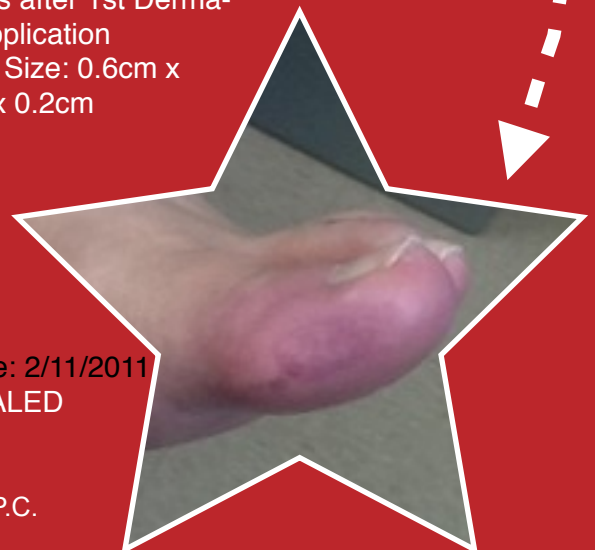Date: 09/8/2010
local wound care
Wound Size: 1.1cm x
1.9cm x 0.3cm



Date: 11/12/2010
2 weeks after 1st Derma-
graft application
Wound Size: 0.6cm x
1.4cm x 0.2cm



Date: 1/14/2011
After 3rd Dermagraft
application
Wound Size: 0.35cm
x 0.6cm x .1cm



Date: 2/11/2011
HEALED



Arch City Foot & Ankle P.C.
Dr. Dennis Timko
drtimko@archcityfoot.com
1-800-707-0215

visit us at www.feetdoc.com