

# ARCH CITY FOOT & ANKLE

## DERMAGRAFT CASE STUDY PRESENTED BY: DR. DENNIS TIMKO DPM

### Patient's history

Patient is a 41 year old male with Type I Diabetes, neuropathy in the lower extremities, and Charcot deformities.

### Diagnosis

6 week old post surgical I & D due to abscess and DM

### Wound treatment & outcome

The patient's ulcer healed completely after only 2 applications of Dermagraft.

Date: 10/11/2010

Pre-Debridement  
Infection with abscess

Date: 11/19/2010

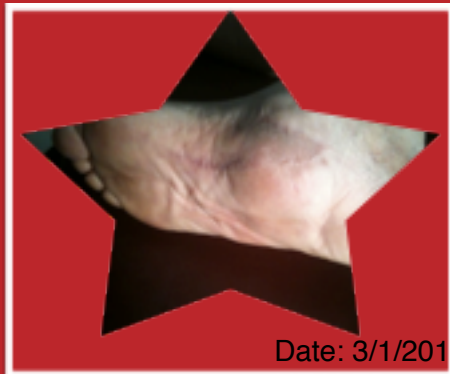
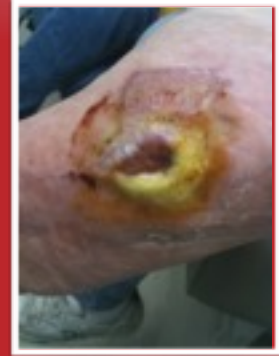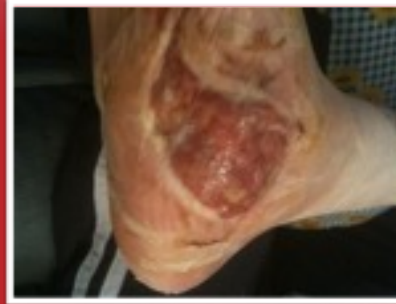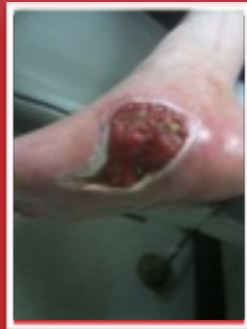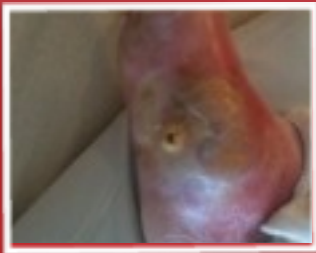Post-Debridement

Date: 11/24/2010

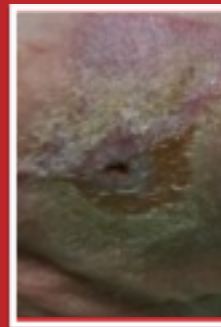Dermagraft #1

Date: 2/11/2011

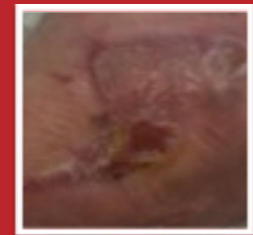Dermagraft #2



Date: 3/1/2011  
HEALED



Date: 3/11/2011  
Eval & debride



Date: 2/23/2011  
Eval & debride