

ARCH CITY FOOT & ANKLE

THERASKIN CASE STUDY PRESENTED BY:

DR. DENNIS TIMKO DPM

Patient's history

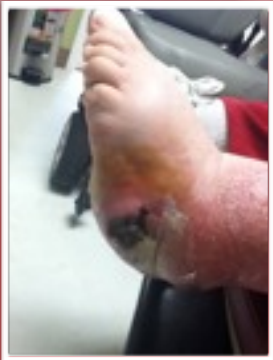Patient is a 64 year old female with Type II Diabetes, neuropathy in the lower extremities, and Charcot deformities.

Diagnosis

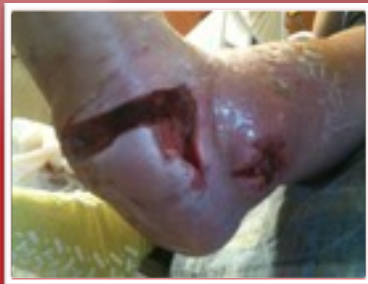6 week old post surgical I & D due to abscess and DM

Wound treatment & outcome

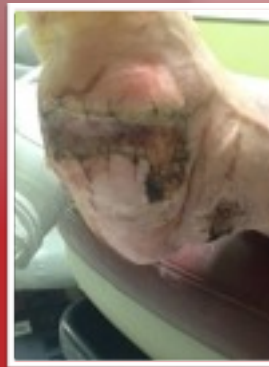
The patient's ulcer healed completely after 2 applications of Theraskin and a percutaneous achilles tendon lengthening.



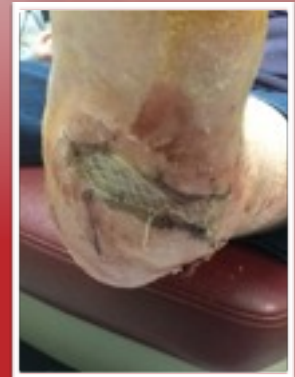
Date: 10/12/2011
Pre-Debridement
Infection with abscess



Date: 10/17/2011
Post-Debridement
Wound Size: 8.2cm x 3.2cm x .6cm

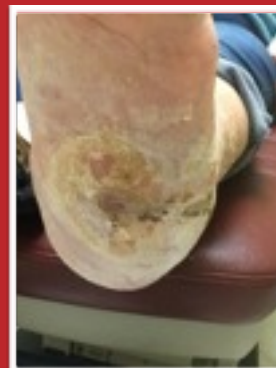
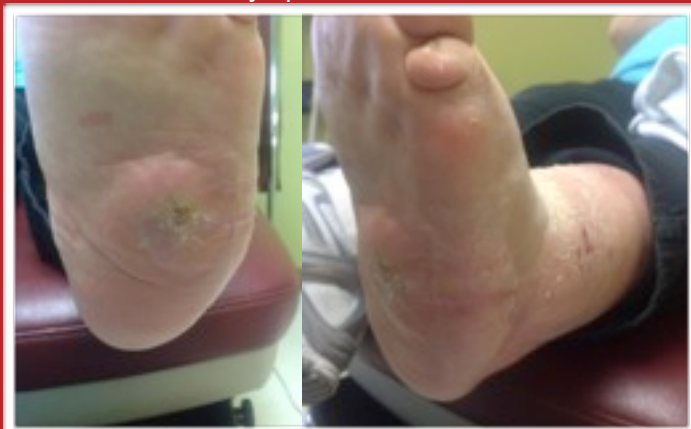
Date: 10/31/2011
Theraskin #1
Wound Size: 8.0cm x 3.0cm x .3cm

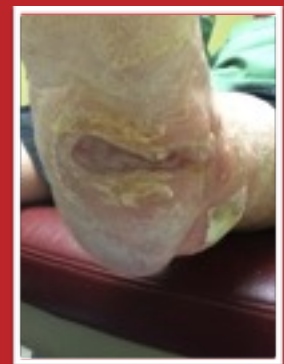

Date: 12/5/2011
Theraskin #2
Wound Size: 7.0cm x 2.0cm x .2cm

Date: 7/2/2012
HEALED after Tendo-
Achilles Lengthening
30 days prior



Date: 1/18/2012
Eval & debride
Wound Size: 3.0cm x 0.4cm x .1cm



Date: 1/4/2012
Eval & debride
Wound Size: 6.0cm x 0.75cm x .2cm